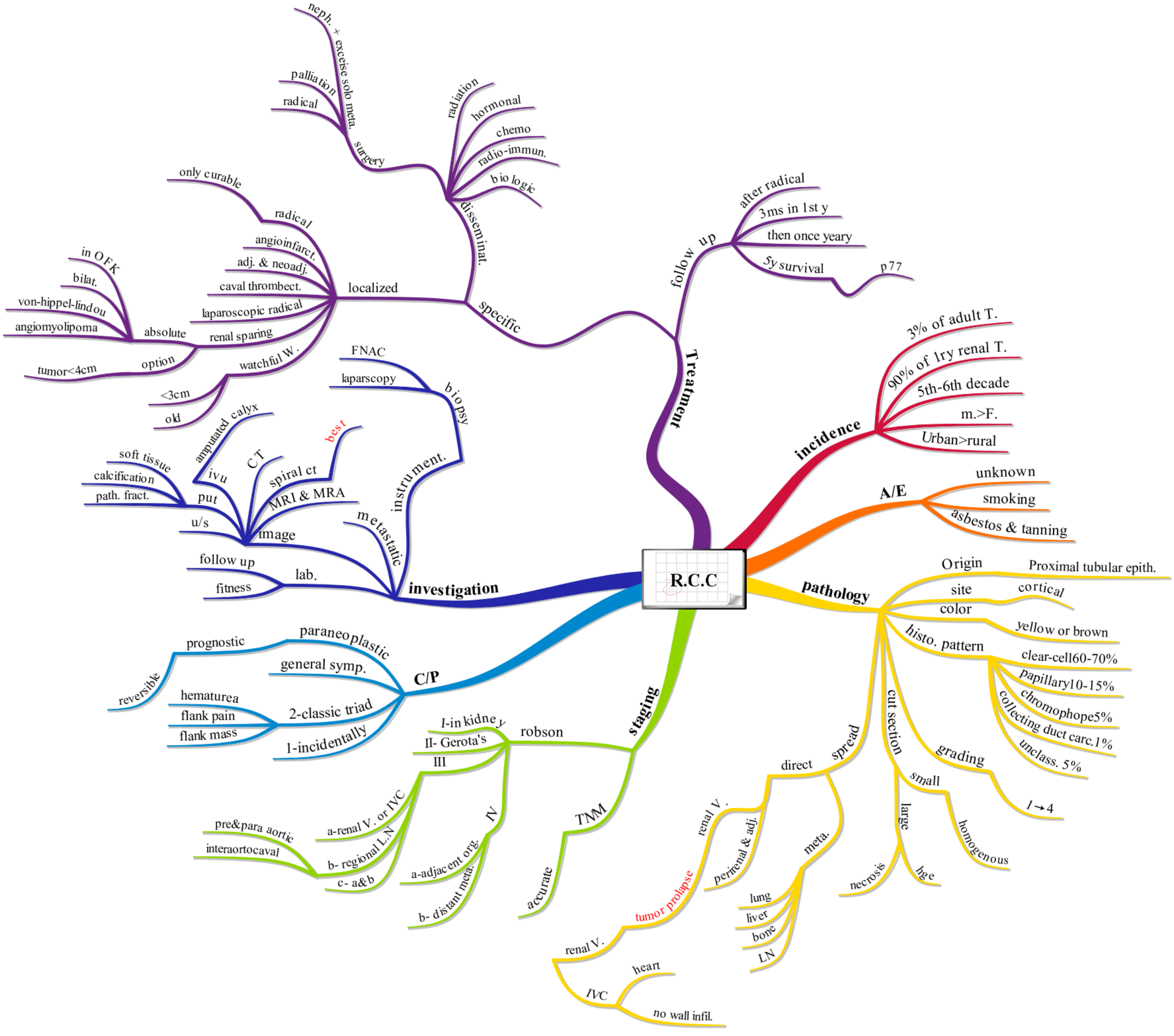
R.C.C
Treatment
follow up
after radical
3ms in 1st y
then once yeary
5y survival
p77
incidence
3% of adult T.
90% of 1ry renal T.
5th-6th decade
m.>F.
Urban>rural
A/E
unknown
smoking
asbestos & tanning
pathology
Origin
Proximal tubular epith.
site
cortical
color
yellow or brown
histo. pattern
clear-cell60-70%
papillary10-15%
chromophope5%
collecting duct carc.1%
unclass. 5%
grading
1→4
cut section
small
homogenous
large
hge
necrosis
spread
direct
renal V.
perirenal & adj.
meta.
lung
liver
bone
LN
tumor prolapse
renal V.
IVC
heart
no wall infil.
staging
TNM
accurate
robson
I-in kidney
II- Gerota's
III
a-renal V. or IVC
b- regional L.N
c- a&b
IV
a-adjacent org.
b- distant meta.
pre&para aortic
interaortocaval
C/P
paraneoplastic
prognostic
general symp.
reversible
hematurea
flank pain
flank mass
2-classic triad
1-incidentally
investigation
image
u/s
ivu
amputated calyx
CT
spiral ct
best
MRI & MRA
soft tissue
calcification
path. fract.
put
instrument.
metastatic
biopsy
FNAC
laparscopy
lab.
follow up
fitness
specific
localized
radical
only curable
angioinfarct.
adj. & neoadj.
caval thrombect.
laparoscopic radical
renal sparing
watchful W.
<3cm
old
option
tumor<4cm
absolute
in OFK
bilat.
von-hippel-lindou
angiomyolipoma
disseminat.
radiation
hormonal
chemo
radio-immun.
biologic
surgery
neph. + exceise solo meta.
palliation
radical